

ULTRASOUND DIAGNOSTICS

DR. JOHN R. REED

DACVIM (CARDIOLOGY)

STATUS: CLOSED

LAST MODIFICATION: AUG 03 2019 11:40:10am

OWNER'S NAME :	RENNEKER, JANET	ANIMAL'S NAME :	G LUNA
WEIGHT :		BIRTH DATE :	NOV 25 2017
AGE :	20 m	GENDER :	F
BREED :	BENGAL	SPECIES :	FELINE
NEUTERED :	NO		
BSA :			
IDENTIFICATION :	PERSONAL	EXAM DATE :	AUG 03 2019
ACCESSION NUMBER :		OPERATOR :	J REED
PERFORMING PHYSICIAN :	J REED	REPORT DATE :	AUG 03 2019

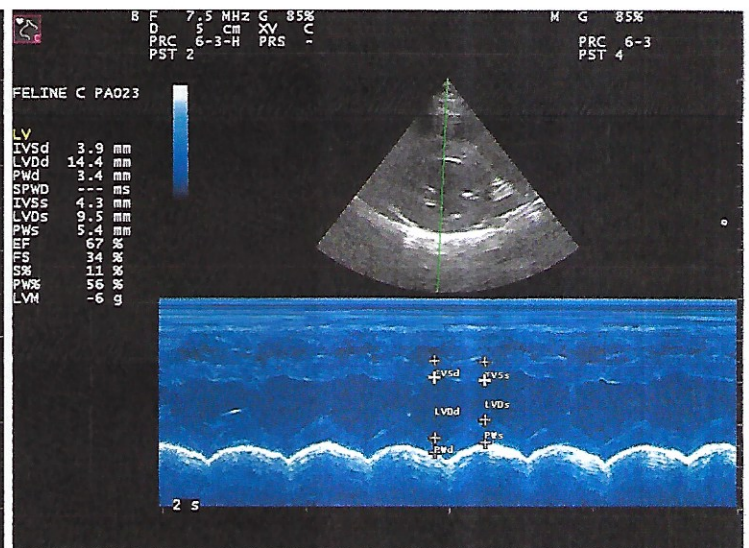
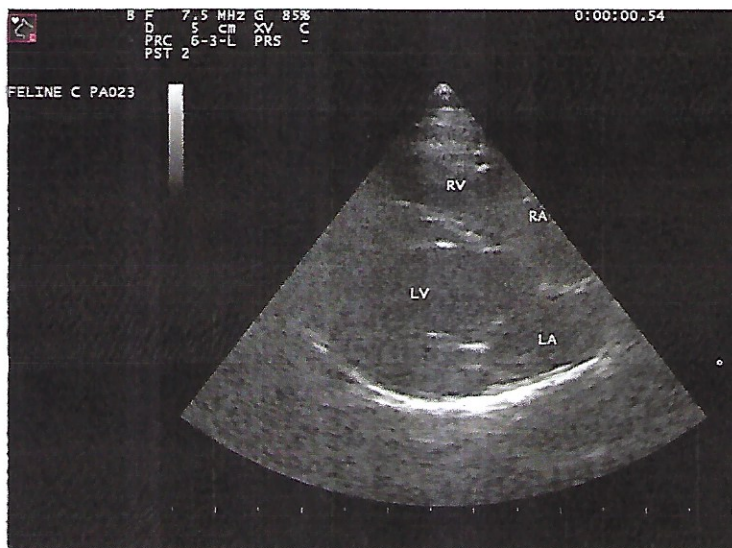
M-MODE

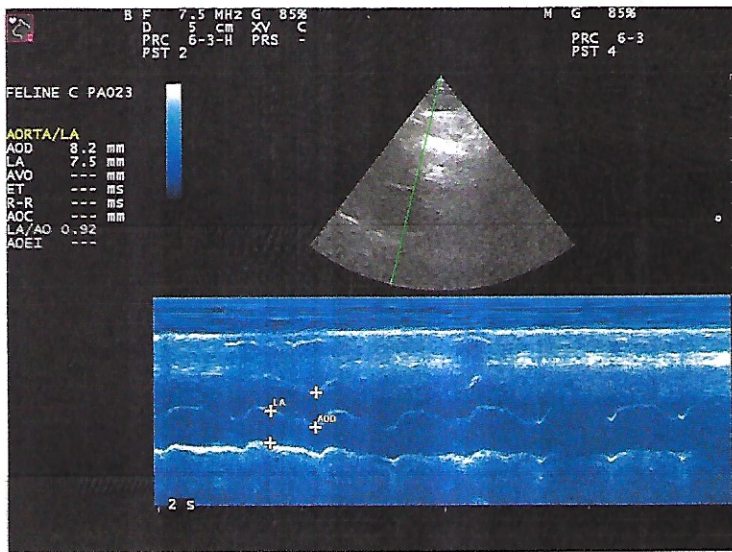
LEFT VENTRICLE

IVS dia : 3.9 mm	LVD dia : 14.4 mm	PW dia : 3.4 mm
IVS sys : 4.3 mm	LVD sys : 9.5 mm	PW sys : 5.4 mm
EF : 67 %	FRACT SH : 34 %	SEP THICK : 11 %
PW THICK : 56 %	LV MASS : -6 g	

AORTA/LEFT ATRIUM

AO DIAM : 8.2 mm	LA : 7.5 mm	LA/AO DIA : 0.92
------------------	-------------	------------------





LEFT VENTRICLE:	NORMAL
LEFT ATRIUM + IAS:	NORMAL LA/Ao RATIO
AORTA:	NORMAL
MITRAL:	NORMAL
PULMONARY:	NORMAL
TRICUSPID:	NORMAL
CONCLUSIONS:	NORMAL CARDIAC EXAMINATION. THERE IS NO EVIDENCE FOR HYPERTROPHIC CARDIOMYOPATHY (HCM) PRESENT.

JOHN REED, DVM